

## Citometrijsko razlikovanje podrijetla hematurije uporabom antitijela na glikoforin A

## Flow cytometric differentiation of the origin of hematuria using fluorescent antiglycophorin antibody

Marija Miloš<sup>1</sup>, Gordana Boršo<sup>2</sup>, Dubravka Čvorišćec<sup>1</sup><sup>1</sup>Klinički zavod za laboratorijsku dijagnostiku, Medicinski fakultet Sveučilišta u Zagrebu i Klinički bolnički centar Zagreb, Zagreb<sup>1</sup>Clinical Institute of Laboratory Diagnosis, Zagreb University School of Medicine and Clinical Hospital Center, Zagreb, Croatia<sup>2</sup>Zavod za nefrologiju i arterijsku hipertenziju, Klinika za unutarnje bolesti, Medicinski fakultet Sveučilišta u Zagrebu i Klinički bolnički centar Zagreb, Zagreb<sup>2</sup>Department of Internal Medicine, Unit of Nephrology and Hypertension, Zagreb University School of Medicine and Clinical Hospital Center, Zagreb, Croatia

## Sažetak

**Uvod:** Laboratorijsko razlikovanje glomerularne i neglomerularne hematurije godinama se uglavnom temelji na ispitivanju morfologije eritrocita u mokraći. Za razliku od eritrocita iz donjih mokraćnih puteva koji su intaktni, pravilnih oblika, glomerularni eritrociti su manji i imaju nepravilne i složene oblike. U ovom radu je ispitana mogućnost razlikovanja podrijetla hematurije protočnom citometrijom, mjerenjem parametara ovisnih o morfološkim značajkama eritrocita u mokraći nakon obilježavanja eritrocita fluorescentnim monoklonskim antitijelima na glikoforin A.

**Materijali i metode:** Svježi uzorci mokraće od ukupno 31 bolesnika s dokazanim glomerularnim i 31 bolesnika s dokazanim urološkim bolestima analizirani su na protočnom citometru FACScan (Becton Dickinson, San Jose, SAD). Eritrociti su izdvojeni od ostalih stanica i nestaničnih elemenata u mokraći bojenjem fluorescentnim monoklonskim antitijelima na glikoforin A, a zatim su mjereni intenziteti rasapa svjetlosti u smjeru ulazne zrake (engl. *forward scatter*, FSC) i okomito na smjer ulazne zrake (engl. *side scatter*, SSC), te je izračunat omjer SSC/FSC. FSC je bio mjera veličine, a SSC mjera oblika eritrocita.

**Rezultati:** Nađena je statistički značajna razlika u izmjerenim vrijednostima FSC ( $P < 0,001$ ), SSC ( $P = 0,016$ ), kao i u omjeru SSC/FSC ( $P < 0,001$ ) između dviju skupina bolesnika. Prema ROC analizi (engl. *Receiver Operating Characteristic*) dobiveni su slijedeći rezultati: za FSC (granična vrijednost za glomerularnu hematuriju  $FSC \leq 49$ ) dijagnostička osjetljivost 90,3% i specifičnost 83,9%; za SSC (granična vrijednost za glomerularnu hematuriju  $SSC > 73$ ) dijagnostička osjetljivost 83,9% i specifičnost 61,3%; za omjer SSC/FSC (granična vrijednost za glomerularnu hematuriju  $SSC/FSC > 2,42$ ) dijagnostička osjetljivost 83,9% i specifičnost 90,3%.

**Zaključak:** Opisana metoda analize eritrocita protočnom citometrijom je jednostavna, automatizirana tehnika za razlikovanja podrijetla hematurije. U odnosu na metodu ispitivanja morfologije eritrocita daje objektivnije i pouzdanije podatke, te omogućuje usmjeravanje bolesnika prema urološkoj, odnosno nefrološkoj problematiki.

**Ključne riječi:** glomerularna hematurija, neglomerularna hematurija, protočna citometrija

## Abstract

**Background:** Glomerular and urinary tract origins of hematuria are differentiated on the basis of urinary red cell morphology. Glomerular erythrocytes are distorted and are smaller than erythrocytes from the lower urinary tract. In this study, we investigated the possibility of flow cytometric differentiation of the origin of hematuria using phycoerythrin-conjugated antibody against glycophorin A, by measuring parameters dependent on morphologic characteristics of urinary erythrocytes.

**Materials and methods:** Fresh urine samples from 31 patients with glomerular disease and 31 patients with urological disease were analyzed on the flow cytometer FACScan (Becton Dickinson, San Jose, USA). Erythrocytes were distinguished from other particles with similar size in urine by staining with phycoerythrin-conjugated antibody against glycophorin A. The intensity of forward scattered light (FSC) and side scattered light (SSC) of the erythrocytes were measured as indicators of red cell size and shape, respectively. Also, the SSC/FSC ratio was calculated.

**Results:** A statistically significant difference in FSC ( $P < 0.001$ ), SSC ( $P = 0.016$ ) and SSC/FSC ratio ( $P < 0.001$ ) values between two groups of patients were found. According to ROC analysis (Receiver Operating Characteristic) the following results were obtained in distinguishing the origin of hematuria: for FSC (cut-off value for glomerular hematuria:  $FSC \leq 49$ ), diagnostic sensitivity 90.3% and specificity 83.9%; for SSC (cut-off value for glomerular hematuria:  $SSC > 73$ ), diagnostic sensitivity 83.9% and specificity 61.3%; for SSC/FSC ratio (cut-off value for glomerular hematuria:  $SSC/FSC > 2.42$ ), diagnostic sensitivity 83.9% and specificity 90.3%.

**Conclusion:** The described flow cytometry analysis is a simple, automated method that can be used to establish distinction between glomerular and non-glomerular bleeding. Compared to the method of urinary red cell morphology examination, it yields more objective and reliable information and allows directing of patients to urologic or nephrologic treatment.

**Key words:** glomerular hematuria, non-glomerular hematuria, flow cytometry.

## Uvod

Asimptomatska mikrohematurija je čest nalaz u općoj populaciji. Učestalost je, prema različitim ispitivanjima, od 0,19% do 16,1%, ovisno o dobi i spolu promatrane populacije, duljini praćenja i broju ispitivanja po bolesniku. Kod starijih muškaraca, koji imaju veći rizik za teže urološke bolesti, učestalost asimptomatske mikrohematurije je 21% (1). Mikrohematurija može biti posljedica benignih stanja bezopasnih za život bolesnika, ali i simptom ozbiljnih bolesti (2,3). S obzirom na to da se u 10-15% bolesnika s hematurijom nađe tumor bubrega, mokraćnog mjehura ili prostate, hematurija se mora smatrati znakom ozbiljne bolesti, dok se ne utvrdi suprotno. Mikrohematurija može biti glomerularna ili neglomerularna. Eritrociti podrijetlom iz glomerula imaju morfološki različite oblike koje nazivamo dismorfčnim eritrocitima. Manji su od eritrocita podrijetlom iz donjih mokraćnih putova, koji su morfološki slični eritrocitima iz periferne krvi (izomorfčni eritrociti). Jednom otkrivena hematurija se mora potvrditi jedanput ili dvaput u kratkom razdoblju, te je potrebno odrediti nježno podrijetlo (4-7).

Morfologija eritrocita u mokraći već desetljećima ispituje se pod svjetlosnim i fazno-kontrastnim mikroskopom. Automatizirane metode (protočni citometri za analizu mokraće, mjerenje MCV na hematološkim analizatorima) daju objektivniji rezultat, ali se kao nedostatak pojavljuje interferencija tzv. urinarnog debria, tj. staničnih i nestaničnih elemenata u mokraći koji su po svojoj veličini slični eritrocitima. Mi smo u ovom radu izbjegli ovu interferenciju predhodnim obilježavanjem eritrocita fluorescentnim monoklonskim antitijelom na glikoforin A (Gly A), molekulu znakovitu za eritroidnu lozu, smještenu na vanjskoj površini stanične membrane. Nakon toga smo eritrocite analizirali na protočnom citometru mjereći parametre koji su mjera morfoloških značajka eritrocita, pa tako i mogući pokazatelji podrijetla eritrocita.

## Materijali i metode

### Ispitanici i uzorci

Ispitivanjem su obuhvaćene dvije skupine bolesnika s hematurijom koji su boravili na Zavodu za nefrologiju i hipertenziju Klinike za unutarnje bolesti KBC Zagreb, te na Klinici za urologiju KBC Zagreb (tablica 1.). Skupina 1 se sastojala od 31 bolesnika (20 muškaraca i 11 žena) kojima je biopsijom bubrega dokazana glomerularna bolest (intenzitet hematurije u sedimentu mokraće: 11 bolesnika s < 5 eritrocita po vidnom polju (veliko povećanje 400×), 11 bolesnika s 5-15 eritrocita po vidnom polju, 9 bolesnika s > 15 eritrocita po vidnom polju). Skupina 2 se sastojala od 31 bolesnika (15 muškaraca i 16 žena) s dijagnosticiranim urološkim bolestima (intenzitet hematurije u sedimentu mokraće: 8 bolesnika s < 5 eritrocita po vidnom polju, 11

## Introduction

Asymptomatic microhematuria is a common finding in general population. The prevalence varies from 0.19% to 16.1% in adults, depending on the age and sex of the population screened, the length of follow-up, and the number of screening studies per patient, while it amounts up to 21% in elderly men who are at an increased risk of severe urologic diseases (1). Microscopic hematuria may be a sign of a serious underlying disease, as well as of some benign conditions not harmful to the patient (2,3). As tumors of the kidney, urinary bladder or prostate are found in 10%-15% of individuals affected by hematuria, it should be considered as a symptom of serious disease until proven otherwise. Microhematuria could be glomerular or non-glomerular. Glomerular erythrocytes are characterized by a wide range of morphological alterations (dysmorphic erythrocytes) and are smaller than those from the lower urinary tract, which maintain their regular round shape (isomorphic erythrocytes). Once detected, hematuria should be confirmed on one or two occasions during a short period, and its origin should be determined (4-7).

The morphology of erythrocytes in urine has previously been investigated by bright-field microscopy and phase contrast microscopy. Automated methods (urinary flow cytometry and MCV measurement on blood cell analyzers) provide more objective results, but are limited by disturbing signals from other cells and non-cellular elements present in the urine (urinary debris). In order to avoid this interference, we stained the erythrocytes with phycoerythrin-conjugated antibody against glycoprotein A (GlyA), a molecule found on the erythrocyte cell membrane. After staining we analyzed morphological characteristics of erythrocytes by flow cytometry in order to differentiate the origin of hematuria.

## Materials and methods

### Patients and samples

Two groups of patients were investigated in this study. They were admitted either at the Division of Nephrology and Hypertension, University Department of Internal Medicine, or at University Department of Urology, Zagreb University Hospital Center (Table 1). Group 1 comprised 31 patients (20 males and 11 females) with biopsy-proven glomerular disease (intensity of hematuria in urinary sediment: 11 patients with < 5 erythrocytes per high power field (HPF, magnification 400×), 11 patients with 5-15 erythrocytes/HPF and 9 patients with > 15 erythrocytes/HPF). Group 2 consisted of 31 patients (15 males and 16 females) with diagnosed urologic disease (intensity of hematuria in urinary sediment: 8 patients with < 5 erythrocytes/HPF, 11 patients with 5-15 erythrocytes /HPF and

TABLICA 1. Značajke ispitivanih bolesnika

TABLE 1. Study patients characteristics

	N	
Group 1 (glomerular diseases)	Progressive glomerulonephritis	4
	Focal glomerular sclerosis	8
	IgA nephropathy	3
	Membranoproliferative glomerulonephritis	9
	Vasculitis	2
	Membrane glomerulonephritis	2
	Systemic lupus nephritis	3
Group 2 (urologic diseases)	Cystitis	6
	Renal stones	5
	Prostatitis	2
	Prostatic adenoma	3
	Renal tumor	1
	Urinary bladder tumor	2
	Renal surgical procedure	6
	Catheter use	6

bolesnika s 5-15 eritrocita po vidnom polju, 12 bolesnika s > 15 eritrocita po vidnom polju), kod kojih nije napravljena biopsija bubrega.

Svim ispitanicima su uzeti uzorci druge jutarnje mokraće koji su analizirani unutar jednog sata. Za bolesnike iz skupine 1 uzorci su uzimani prije biopsije.

Istraživanje je odobrilo bolničko etičko povjerenstvo.

#### Priprema uzoraka

Za analizu su uzeta dva alikvota od po 10 mL mokraće i centrifugirana 10 min na 2500 okr/min. Supernatanti su odliveni, te su sedimenti dva puta isprani s 5 mL fosfatnog pufera pH 7,0 i svaki puta ponovno centrifugirani pod istim uvjetima. Nakon centrifugiranja je u jednu epruvetu dodano 10 µL antitijela na Gly A izravno vezanog na fluorescentnu boju fikoeritrin (RPE-Conjugated Monoclonal Mouse Anti-Human Glycophorin A, Dako A/S Denmark) (100 mg/L), a u drugu epruvetu koja je predstavljala negativnu kontrolu dodano je 10 µL mišjeg IgG<sub>1</sub> izravno vezanog na fluorescentnu boju fikoeritrin (RPE-Conjugated Mouse IgG<sub>1</sub> Negative Control for Flow Cytometry, Dako A/S Denmark) (100 mg/L). Nakon inkubacije od 10 min na sobnoj temperaturi ponovljen je postupak ispiranja s 3 mL fosfatnog pufera pH 7,0, centrifugiranja pod istim uvjetima, te odlijevanja supernatanta. Konačno su stanice resuspendirane u 500 µL fosfatnog pufera pH 7,0.

#### Analizator i metoda

Predhodno pripremljeni uzorci mokraće analizirani su na protočnom citometru FACScan u programu Cellquest™

12 patients with > 15 erythrocytes/HPF). Kidney biopsy was not performed in any group 2 patient.

Second morning urine samples were collected from all patients, transported to the laboratory and processed within an hour. In group 1 patients, urine samples were obtained before biopsy.

The study was approved by the Hospital Ethics Committee.

#### Preparation of samples

For analysis, 2x10 mL of each urine sample were centrifuged for 10 minutes at 2500 rpm, the supernatants were decanted and sediments rinsed twice with 5 mL of phosphate buffer pH 7.0. After centrifugation, 10 µL of phycoerythrin-conjugated antibody against glycophorin A (RPE-Conjugated Monoclonal Mouse Anti-Human Glycophorin A, Dako A/S Denmark) (100 mg/L) were added into the first test tube, and 10 µL of phycoerythrin-conjugated murine IgG<sub>1</sub> antibody (RPE-Conjugated Mouse IgG<sub>1</sub> Negative Control for Flow Cytometry, Dako A/S Denmark) (100 mg/L) to the second test tube for negative control. Both test tubes were incubated for 10 minutes at room temperature, rinsed with 3 mL of phosphate buffer pH 7.0 and centrifuged. Finally, the sediments were resuspended in 500 µL of phosphate buffer pH 7.0.

#### Instruments and methods

Prepared samples were analyzed on a FACScan flow cytometer using Cellquest™ program (Becton Dickinson, San Jose, USA), with argon laser as light source of 488 nm wa-

(Becton Dickinson, San Jose, SAD), uz argonski laser kao izvor svjetlosti valne duljine 488.

Od ukupnog broja od 10.000 stanica izdvojeni su eritrociti kao stanice s pozitivnom fluorescencijom, te su im izmjereni slijedeći parametri: rasap svjetlosti u smjeru ulazne zrake (engl. *forward scatter*, FSC) i rasap svjetlosti okomit na smjer ulazne zrake (engl. *side scatter*, SSC). Instrument je automatski računao srednji FSC i SSC za svaki uzorak. FSC je parametar proporcionalan veličini stanice, a SSC je kao parametar ovisan o stupnju granuliranosti, tj. složenosti unutarnje strukture stanice ili složenosti jezgre stanice, bio mjera oblika eritrocita, budući da je eritrocit stanica bez jezgre. Na kraju je izračunat i omjer SSC/FSC kako bi se izbjegao utjecaj veličine eritrocita na oblik.

### Statistička analiza

Za statističku obradu podataka primijenjen je statistički program GraphPadPrism 5 (GraphPad Software, Inc., USA) verzija 5.01. Za ispitivanje normalnosti raspodjele podataka primijenjen je Kolmogorov-Smirnovljev test. Podaci koji slijede normalnu raspodjelu prikazani su aritmetičkom sredinom i standardnom devijacijom, a podaci s asimetričnom raspodjelom prikazani su medijanom i interkvartilnim rasponom. Statistička značajnost razlike među skupinama ispitana je pomoću Mann-Whitney testa. Kriterij za statističku značajnost bio je  $P < 0,05$ . ROC analiza (engl. *Receiver Operating Characteristic*) je upotrijebljena za procjenu dijagnostičkih mogućnosti mjerenih parametara.

### Rezultati

Rezultati mjerenja FSC i SSC na protočnom citometru, kao i omjera SSC/FSC prikazani su u tablici 2. Nađena je statistički značajna razlika za sva tri parametra između dviju skupina bolesnika.

Rezultati ROC analize prikazani su u tablici 3. Za sva tri parametra prikazane su dobivene površine ispod krivulje (engl. *area under the curve*, AUC) s pripadajućim 95%-tnim intervalima pouzdanosti, optimalne granične vrijednosti, te vrijednosti za dijagnostičku osjetljivost i specifičnost. Dobivena je statistički značajna razlika između dobivenih AUC za FSC i SSC ( $P = 0,013$ ), te za omjer SSC/FSC i SSC ( $P$

length. Firstly, erythrocytes were selected as fluorescent positive cells on cytogram, in a total of 10,000 cells. Then, two flow cytometric parameters were measured: forward scatter light intensity (FSC) and side scatter light intensity (SSC). Mean FSC and SSC values were automatically calculated by the instrument for each sample. It is generally thought that FSC and SSC are proportional to cell size and polymorphism of nucleus, respectively. We used FSC as a measure of erythrocyte size and SSC as an indicator of cell surface unevenness because erythrocytes had lost their nuclei. Also, the SSC/FSC ratio was calculated to eliminate the influence of cell size on the SSC parameter.

### Statistical analysis

Statistical analysis was performed by using GraphPadPrism 5 statistical program (GraphPad Software, Inc., USA) version 5.01. Variables were tested for normality using the Kolmogorov-Smirnov test. Parametric data were expressed as arithmetic mean and standard deviation, whereas nonparametric data were expressed as median and interquartile range. Mann-Whitney test was used for between-group difference testing. Values of  $P < 0.05$  were considered statistically significant. The Receiver Operating Characteristic (ROC) analysis was used to illustrate diagnostic performance of the study method parameters.

### Results

The results obtained for FSC, SSC and SSC/FSC ratio are shown in Table 2. We found a statistically significant difference in all parameters between the two groups of patients.

The results of ROC analysis are shown in Table 3. The areas under the curve (AUC) obtained with the respective 95% confidence intervals as well as optimal cut-off values and diagnostic sensitivities and specificities are presented for all three parameters. A statistically significant difference between the AUC obtained was found for FSC and SSC ( $P = 0.013$ ), and for SSC/FSC ratio and SSC ( $P < 0.001$ ). Difference between the AUC obtained for FSC and

**TABLICA 2.** Rezultati analize na protočnom citometru

Parameter	Group 1 N = 31	Group 2 N = 31	P
FSC	29.0 (26.0-37.0)*	81.8±42.0§	< 0.001
SSC	104.0 (87.0-125.0)*	70.5 (43.0-110.0)*	0.016
SSC/FSC	3.72 (3.04-4.12)*	0.89 (0.69-1.90)*	< 0.001

FSC - forward scattered light; SSC - side scattered light; \* Median (interquartile range); § Mean ± SD

**TABLE 2.** Results of flow cytometric analysis

< 0,001), dok razlika između dobivenih AUC za FSC i omjer SSC/FSC nije bila statistički značajna. Na slici 1. prikazane su ROC krivulje za FSC, SSC i omjer SSC/FSC, s graničnim vrijednostima za glomerularnu hematuriju.

Znakoviti rezultati analize mokraće protočnom citometrijom kod bolesnika s glomerularnom i neglomerularnom hematurijom prikazani su na slici 2. Za bolesnika s glomerularnom hematurijom dobivene su slijedeće vrijednosti: FSC = 31,2; SSC = 110,4; SSC/FSC = 3,54; a za bolesnika s neglomerularnom hematurijom FSC = 65,8; SSC = 36,5; SSC/FSC = 0,54.

Na slici 3. prikazan je primjer analize dvaju uzoraka mokraće od istog bolesnika uzetih prije i neposredno poslije biopsije bubrega. Radilo se o bolesniku iz skupine 1 s dokazanom bolesti glomerula. U uzorku mokraće uzetom prije biopsije dobivene su slijedeće vrijednosti: FSC = 40,7; SSC = 99,9; SSC/FSC = 2,45; a u uzorku mokraće uzetom neposredno nakon biopsije FSC = 78,2; SSC = 69,4; SSC/FSC = 0,89.

## Rasprava

Pouzdana otkrivanje podrijetla hematurije ima veliko kliničko značenje. Mikroskopske tehnike su jeftine, ali komplicirane, nereproducibilne i subjektivne (1,8-15). Objektivnije, automatizirane metode (protočni citometri za analizu mokraće, mjerenje MCV na hematološkim analizatorima) su ograničene interferencijom tzv. urinarnog debria (16-25).

U ovom smo radu ispitali metodu analize mokraće protočnom citometrijom kao metodom za razlikovanje podrijetla hematurije, uz predhodno bojanje eritrocita fluorescentnim antitijelima na GlyA, čime je izbjegnuta interferencija urinarnog debria. Nakon izdvajanja eritrocita mjereni

SSC/FSC ratio was not statistically significant. ROC curves for FSC, SSC and SSC/FSC ratio are shown in Figure 1, with cut-off values for glomerular hematuria.

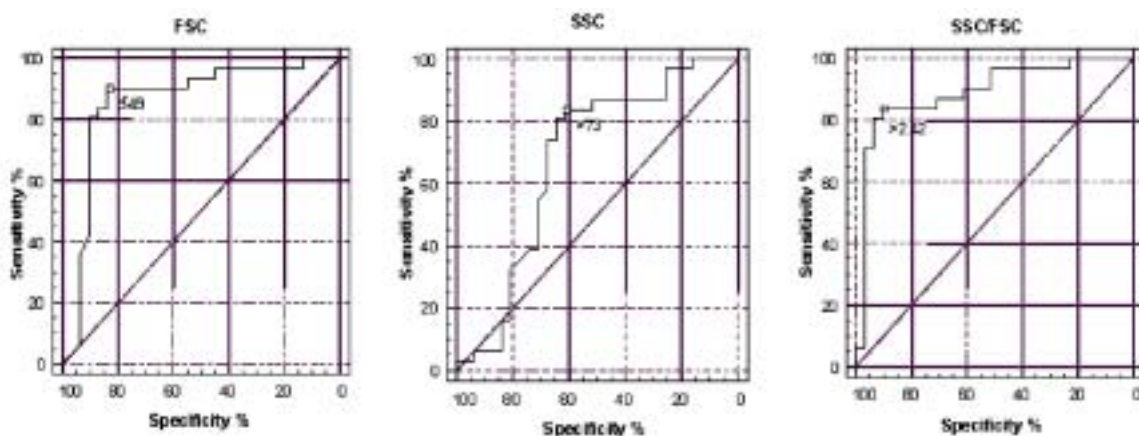
Typical patterns of flow cytometry urine testing in patients with glomerular and non-glomerular hematuria are shown in Figure 2. The values obtained for patient with glomerular hematuria were as follows: FSC = 31.2; SSC = 110.4; and SSC/FSC = 3.54; and for patient with non-glomerular hematuria FSC = 65.8; SSC = 36.5; and SSC/FSC = 0.54.

An example of flow cytometry urine analysis of two samples from the same patient obtained prior and following biopsy is shown in Figure 3. The patient was from group 1, with biopsy proven glomerular kidney disease. The values obtained in the first sample were as follows: FSC = 40.7; SSC = 99.9; and SSC/FSC = 2.45, and in the second sample FSC = 78.2; SSC = 69.4; and SSC/FSC = 0.89.

## Discussion

Reliable determination of the origin of hematuria is of great clinical importance. Although microscopic techniques are cost-effective, they are time-consuming and associated with inter-observer variations (1,8-15). Although more objective results have been obtained with the introduction of automated methods (urinary flow cytometry and MCV measurement on blood cell analyzers), identification of erythrocytes only by size leads to the interference of urinary debris (16-25).

In the present study, we stained erythrocytes prior to flow cytometry analysis with phycoerythrin-conjugated antibody against Gly A, a glycoprotein on erythrocyte membrane specific for erythroid cell line, and then analyzed morphological characteristics of erythrocytes by



**SLIKA 1.** ROC krivulje za razlikovanje podrijetla hematurije pomoću vrijednosti FSC, SSC i omjera SSC/FSC

**FIGURE 1.** ROC curves for discrimination of the origin of hematuria by flow cytometry method according to FSC, SSC and SSC/FSC ratio.

su parametri koji su pokazatelji morfoloških značajka eritrocita u mokraći: FSC kao pokazatelj veličine eritrocita i SSC kao pokazatelj složenosti oblika eritrocita. Također se izračunao omjer SSC/FSC kao mogući bolji pokazatelj morfoloških značajka eritrocita. Metoda nije dosad opisana u literaturi. Tanaka i sur. su opisali metodu obilježavanja eritrocita fluorescentnim antihemoglobinskim antitijelima (26). Kao što je poznato, hemoglobin je smješten unutarstanično, pa je za obilježavanje bila potrebna predhodna permeabilizacija stanične membrane eritrocita, što kod antitijela na Gly A nije slučaj, jer je Gly A smješten na površini stanice eritrocita.

Mjerenjem parametara FSC i SSC te izračunavanjem omjera SSC/FSC dobivene su statistički značajne razlike u rezultatima između skupine bolesnika s glomerularnom i neglomerularnom hematurijom (tablica 2.).

ROC analiza je pokazala mogućnost pouzdanog razlikovanja između dviju skupina bolesnika mjerenjem parametara protočne citometrije, osobito FSC i omjera SSC/FSC (tablica 3., slika 1.). Primjerice, prema omjeru SSC/FSC, od 31 bolesnika iz skupine 1 glomerularna hematurija je potvrđena kod njih 26 (osjetljivost 83,9%), dok su kod 5 ispitanika dobiveni rezultati ukazivali na neglomerularnu hematuriju (16,1% lažno negativnih rezultata). Kod 3 od 5 ispitanika nađena je hematurija niskog intenziteta (1+ na test traci, < 5 eritrocita po vidnom polju uz veliko povećanje u sedimentu mokraće), što bi moglo biti razlogom za lažno negativne rezultate. Lažno pozitivni rezultati glomerularne hematurije dobiveni su kod 3 ispitanika (9,7%) iz skupine 2 (specifičnost 90,3%). Kod 2 ispitanika je pokazana visoka osmolalnost mokraće (626 i 951 mOsmol/kg), što je mogući uzrok promjene u obliku eritrocita, pa tako i lažno pozitivnog rezultata za glomerularnu hematuriju. Kod glomerularne hematurije zapažene su prosječno niže vrijednosti FSC i više vrijednosti SSC u odnosu na neglomerularnu hematuriju. Također su dobivene više vrijednosti omjera SSC/FSC kod glomerularne hematurije. Ovakvi su rezultati potvrdili pretpostavke o „glomerularnim“ eritrocitima koji su manji po veličini, ali imaju nepravilne

measuring FSC and SSC as indicators of erythrocyte size and shape, respectively. Also, the SSC/FSC ratio was calculated. To our knowledge, this method has not been previously reported in the literature. The method of erythrocyte labeling with fluorescein-labeled antihemoglobin antibodies has been reported by Tanaka *et al.* (26). As it is well known, hemoglobin is a molecule localized inside the cell, and previous cell membrane permeabilization is necessary for erythrocyte labeling. This was not the case with antibodies against Gly A because Gly A is a molecule found on the erythroid cell membrane.

We found statistically significant differences in FSC, SSC and SSC/FSC ratio values between patients with glomerular and urologic source of bleeding (Table 2).

The ROC curve analysis revealed good discrimination between the two groups of patients according to the measured parameters, FSC and SSC/FSC ratio in particular (Table 3, Figure 1). Based on the SSC/FSC ratio, glomerular hematuria was confirmed in 26 of 31 group 1 patients (sensitivity 83.9%), while in 5 patients (16.1% false negative results) non-glomerular hematuria was found. Among these 5 samples, low intensity hematuria was observed in 3 samples (1+ or less by dipstick testing, < 5 erythrocytes/HPF in urine sediment analysis). False positive results of glomerular hematuria were obtained in 3 (9.7%) group 2 patients (specificity 90.3%). Two of them had high urine osmolality values (626 and 951 mOsmol/kg), which was the most likely cause of change in erythrocyte shape and of the false positive result.

As expected, we observed lower FSC and higher SSC values for glomerular hematuria, as compared with non-glomerular hematuria (Figure 2). Also, the SSC/FSC ratios were significantly higher in glomerular hematuria. These results confirmed the characteristics of “glomerular” erythrocytes that are small but of irregular shape, unlike “non-glomerular” erythrocytes which are larger and smooth-shaped. In the FSCxSSC scatterplot (Fig. 2) of a patient with glomerular hematuria (A), a large prominent cell population was evident with relatively low FSC va-

**TABLICA 3.** Rezultati ROC analize

	FSC	SSC	SSC/FSC ratio
AUC	0.862 *	0.678 *§	0.892 §
95% CI	0.757–0.967	0.537–0.819	0.805–0.979
Optimal cut-off value	49	73	2.42
Sensitivity (%)	90.3	83.9	83.9
Specificity (%)	83.9	61.3	90.3

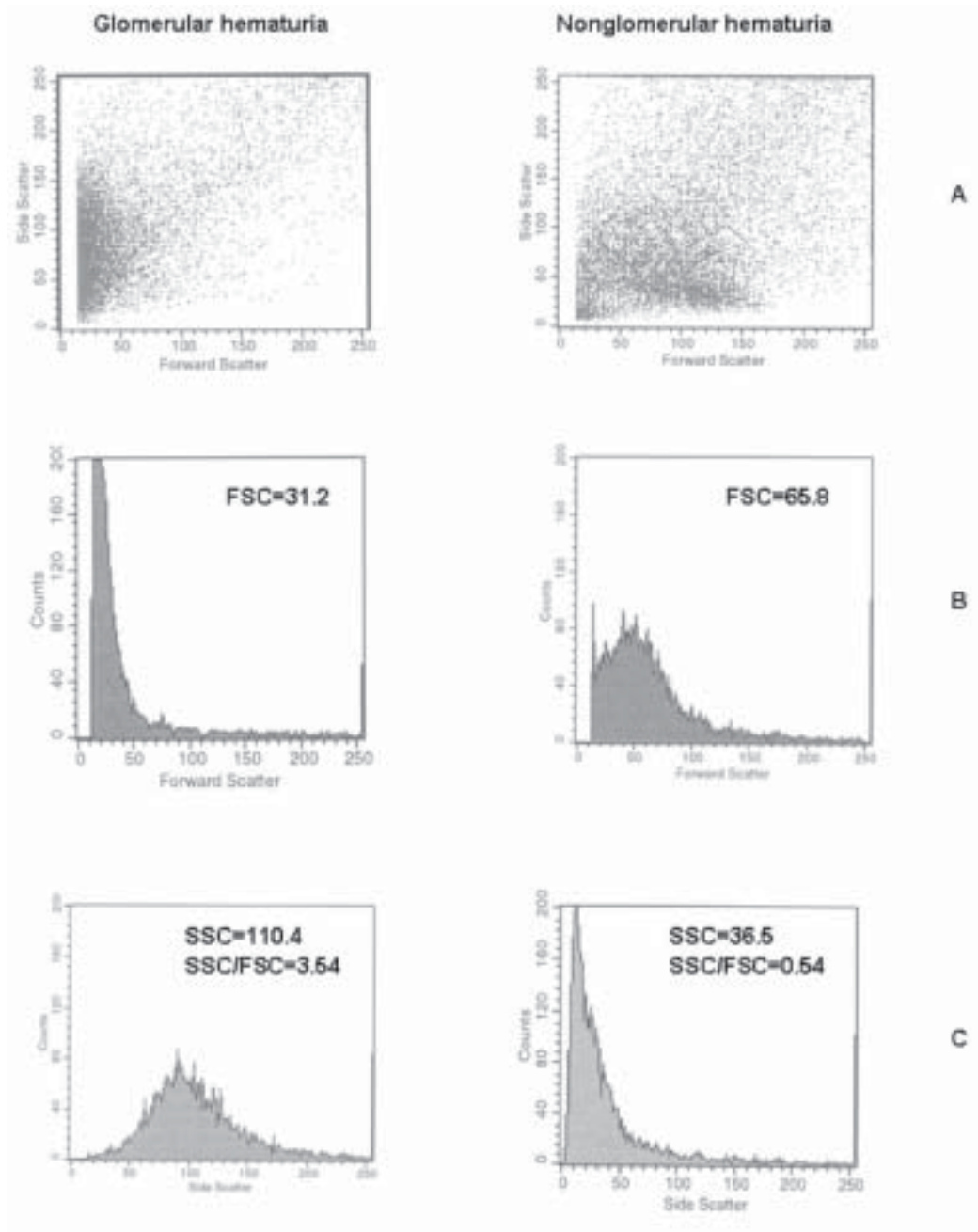
FSC - forward scattered light; SSC - side scattered light; AUC - area under the curve; \* statistically significant difference between AUC according to FSC and SSC (P = 0.013); § statistically significant difference between AUC according to SSC/FSC and SSC (P < 0.001)

**TABLE 3.** Results of ROC analysis

oblike, za razliku od „neglomerularnih“ eritrocita koji su veći i imaju pravilan oblik. Na slici 2. u dvoparametrijskom prikazu FSC×SSC kod bolesnika s glomerularnom hematurijom (A) jasno se vidi stanična populacija s relativno niskim vrijednostima FSC i širokom distribucijom po ordinati koja predstavlja vrijednosti SSC. Kod bolesnika s neglome-

lues but with broad distribution of SSC values. In non-glomerular hematuria, however, a cell population could be observed whose SSC distribution was not so broad, but FSC values were remarkably increased.

An occurrence of a new cell population following kidney biopsy, as compared to pre-biopsy finding, was observed



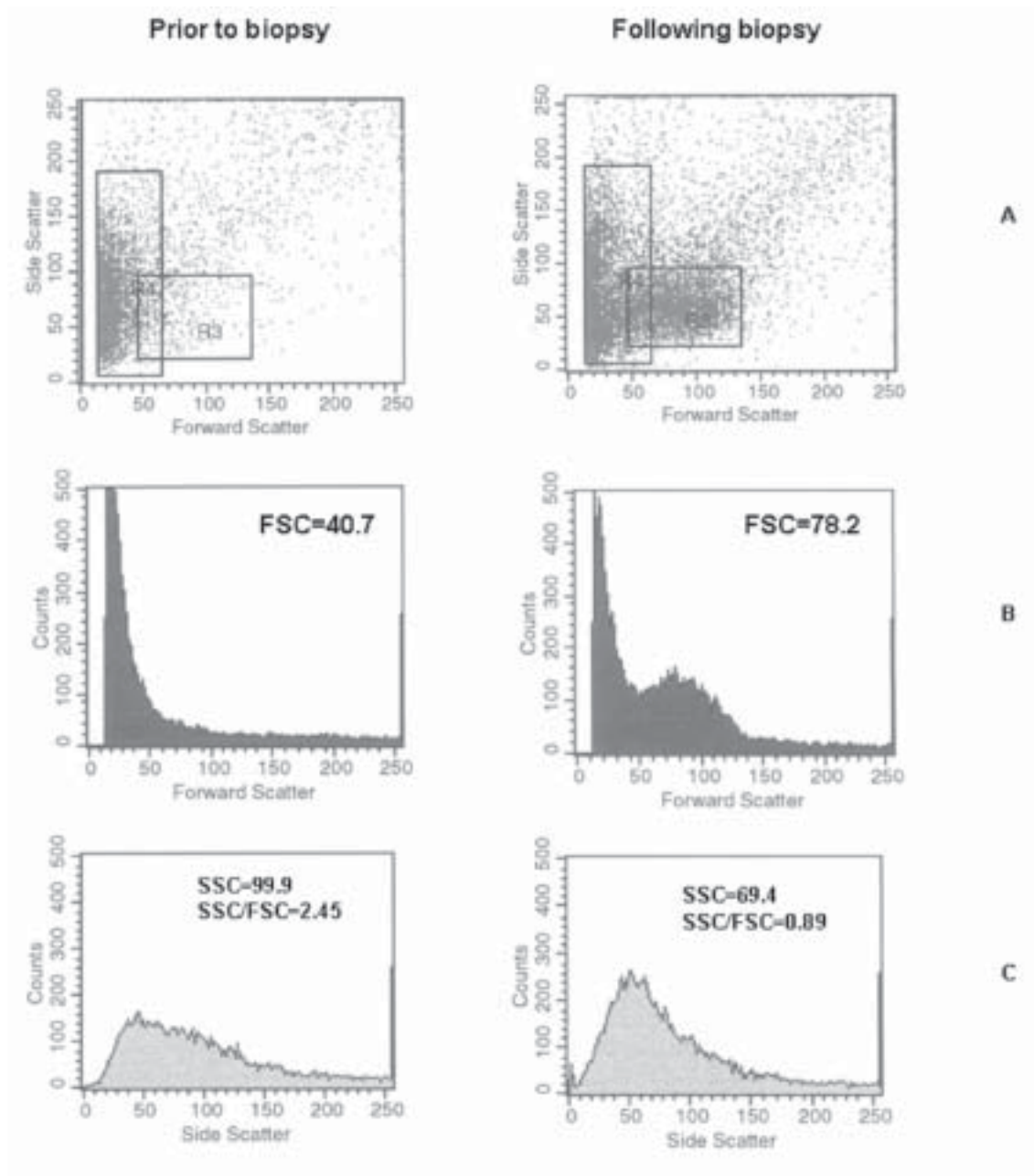
**SLIKA 2.** Tipičan nalaz analize mokraće na protočnom citometru kod bolesnika s glomerularnom i neglomerularnom hematurijom: FSCxSSC (A), raspodjela eritrocita prema FSC (B) i SSC (C).

**FIGURE 2.** The typical patterns of flow cytometry urin analysis in patients with glomerular and non-glomerular hematuria: FSCxSSC scatterplots (A), distribution of erythrocytes according to FSC (B) and SSC (C).

rularnom hematurijom, međutim, eritrociti su u prikazu FSC×SSC smješteni potpuno drukčije, s niskim vrijednostima SSC i višim vrijednostima FSC.

U primjeru na slici 3A. vidi se jasno pojava nove populacije eritrocita u uzorku istog bolesnika uzetom nakon biopsije bubrega u usporedbi s uzorkom uzetim prije biopsije. Zbog toga su i dobiveni rezultati mjerenja bili potpuno različiti prije i poslije biopsije, što bi moglo dovesti do

in patients undergoing this diagnostic procedure (Figure 3A). This new cell population gave rise to a change in FSC, SSC and SSC/FSC values, and could lead to misinterpretation of the type of hematuria. However, the patient was affected by glomerular disease, and a nonglomerular erythrocyte population occurred in his urine sample due to the invasive diagnostic procedure, presenting as mixed hematuria. Flow cytometry analysis program al-



**SLIKA 3.** Primjer nalaza mokraće na protočnom citometru kod istog bolesnika prije i nakon biopsije bubrega: FSC×SSC (A), raspodjela eritrocita prema FSC (B) i SSC (C).

**FIGURE 3** Flow cytometry analysis of two samples from the same patient obtained prior and following kidney biopsy: FSC×SSC scatterplots (A), distribution of erythrocytes according to FSC (B) and SSC (C).



pogrešne interpretacije da se radi o neglomerularnoj hematuriji. Radi se, međutim, o bolesniku s glomerularnom bolešću kod kojeg se zbog invazivnog dijagnostičkog postupka pojavila populacija neglomerularnih eritrocita u mokraći, što je prolazna pojava i predstavlja miješanu hematuriju. Program za analizu na protočnom citometru omogućava uočavanje ovakvih slučajeva, ali i zasebnu analizu i praćenje dviju populacije eritrocita kod miješane hematurije.

Prema pokazanim rezultatima, opisana metoda na protočnom citometru omogućava pouzdano razlikovanje podrijetla eritrocita u mokraći. Bilo bi, međutim, korisno potvrditi dobivene rezultate na većem broju ispitanika, kao i ispitati osjetljivost metode kod blage hematurije, tj. malog broja eritrocita u mokraći. Ograničenje ovoga ispitivanja svakako je činjenica da ispitanici iz skupine 2 nisu bili podvrgnuti biopsiji bubrega, pa moguća glomerularna bolest kod njih nije bila isključena. Kao i kod ostalih metoda za razlikovanje podrijetla hematurije potrebno je analizu provesti u kratkom razdoblju nakon uzorkovanja, pogotovu kod izrazito koncentriranih ili razrijeđenih uzoraka mokraće. Opisana metoda je objektivna i jednostavna, te je primjenjiva u svakodnevnom rutinskom radu laboratorija. Kliničarima daje mogućnost bržeg usmjeravanja bolesnika prema nefrološkoj odnosno urološkoj problematiki, kao i izbjegavanje skupih i invazivnih dijagnostičkih postupaka koji se provode kako bi se otkrio uzrok hematurije. Laboratorijskim pak stručnjacima predstavlja mogućnost nove primjene protočne citometrije, i to u području urologije i nefrologije.

### Zahvala

Neizmjereno smo zahvalni preminuloj kolegici dr. sci. Branki Užarević za njezin doprinos ovom radu, korisnim savjetima i pomoći na području protočne citometrije.

### Adresa za dopisivanje:

Mr.sc. Marija Miloš  
Klinički zavod za laboratorijsku dijagnostiku  
Klinički bolnički centar „Zagreb“  
Kišpatićeva 12  
10000 Zagreb  
Hrvatska  
e-pošta: marijamilos1@yahoo.com  
tel: 01 2367-263  
faks: 01 2367-395

lows for detection of such cases and also separate analysis and follow-up of two erythrocyte populations in mixed hematuria.

According to our results, the method described that identifies only erythrocyte from urine by staining with phycoerythrin-conjugated antibody against Gly A enables reliable differentiation of the origin of hematuria. It would, nevertheless, be useful to confirm the results obtained in a larger number of subjects, and to examine the method sensitivity for mild hematuria. The limitation of the study was the possibility of concomitant glomerular disease in group 2 patients, which was not excluded by kidney biopsy. Also, as in other methods used to distinguish the origin of hematuria, the analysis should be performed shortly after sampling, particularly of highly concentrated or diluted urinary samples.

The method described seems to be objective, simple and applicable in routine laboratory practice. It provides clinicians with the possibility to rapidly direct patients to nephrologic or urologic examination and thus to avoid expensive or invasive diagnostic procedures performed to detect the cause of hematuria. To laboratory professionals, it is a new opportunity to use flow cytometry in the fields of urology and nephrology.

### Acknowledgment

We are very grateful to the late Dr Branka Uzarevic for her contribution to this study, for advice and help regarding flow cytometry.

### Corresponding author:

Marija Milos, Msc  
Clinical Institute of Laboratory Diagnosis  
Clinical Hospital Center Zagreb  
Kispaticeva 12  
10000 Zagreb  
Croatia  
e-mail: marijamilos1@yahoo.com  
phone: +385 1 2367-263  
fax: +385 1 2367-395

## Literatura/References

- Grossfeld GD, Wolf JS, Litvin MS, Hricak H, Shuler CL, Agerter DC, et al. Asymptomatic microscopic hematuria in adults: summary of the AUA Best Practice Policy Recommendations. *Am Fam Physician* 2001;63:1145-54.
- Rockall AG, Newman-Sanders APG, Al-Kutoubi MA, Vale JA. Haematuria. *Postgrad Med J* 1997;73:129-36.
- Guder WG, Hofmann W. Urinproteindiagnostik. In: Thomas L, Fateh-Moghadam A, Guder WG, Hofmann W, Reiber H, Lammers M, eds. *Proteindiagnostik Diagnose Therapiekontrolle*. Frankfurt/Main: Behringwerke AG; 1991. pp.110-39.
- Schröder FH. Microscopic haematuria. *Br Med J* 1994;309:70-2.
- Thomas L, Boege F. Kidney and urinary tract. In: Thomas L, ed. *Clinical laboratory diagnostics*. 1st ed. Frankfurt/Main: TH-Books-Verl.-Ges; 1998. pp.362-400.
- Thaller TR, Wang LP. Evaluation of asymptomatic microscopic hematuria in adults. *Am Fam Physician* 1999;60:1143-54.
- Jaffe JS, Ginsberg PC, Gill R, Harkaway RC. A new diagnostic algorithm for the evaluation of microscopic hematuria. *Urology* 2001;57:889-94.
- Fasset RG, Horgan BA, Mathew TH. Detection of glomerular bleeding by phase-contrast microscopy. *Lancet* 1982;1:1432-4.
- Köhler H, Wandel E, Brunck B. Acanthocyturia – a characteristic marker for glomerular bleeding. *Kidney Int* 1991;40:115-20.
- Mohammad KS, Bdesha AS, Snell ME, Witherow RON, Coleman DV. Phase contrast microscopic examination of urinary erythrocytes to localise source of bleeding: an overlooked technique? *J Clin Pathol* 1993;46:642-5.
- Lettgen B, Wohlmuth A. Validity of G1-cells in the differentiation between glomerular and non-glomerular haematuria in children. *Pediatr Nephrol* 1995;9:435-7.
- Dinda AK, Saxena S, Guleria S, Tiwari SC, Dash SC, Srivastava RN, et al. Diagnosis of glomerular haematuria: role of dysmorphic red cell, G1 cell and bright-field microscopy. *Scand J Clin Lab Invest* 1997;57:203-8.
- Fogazzi GB, Ponticelli C, Ritz E. The formed elements of the urinary sediment. In: Fogazzi GB, Ponticelli C, Ritz E, eds. *The urinary sediment*. 2<sup>nd</sup> ed. Milan: Masson S.p.A.; 1999. pp.29-134.
- Zaman Z, Proesmans W. Dysmorphic erythrocytes and G1 cells as markers of glomerular hematuria. *Pediatr Nephrol* 2000;14:980-4.
- Nagahama D, Yoshiko K, Watanabe M, Morita Y, Iwatani Y, Matsuo S. A useful new classification of dysmorphic urinary erythrocytes. *Clin Exp Nephrol* 2005;9:304-9.
- Shichiri M, Oowada A, Nishio Y, Tomita K, Shiiga T. Use of autoanalyser to examine urinary-red-cell morphology in the diagnosis of glomerular haematuria. *Lancet* 1986;2:781-2.
- Docci D, Delvecchio C, Turci A, Turci F, Baldrati L, Martinelli A. Detection of glomerular bleeding by urinary-red-cell-size distribution. *Nephron* 1988;50:380-2.
- DeMetz M, Schiphorst PP, Go RH. The analysis of erythrocyte morphologic characteristics in urine using a hematologic flow cytometer and microscopic methods. *Am J Clin Pathol* 1991;95:257-61.
- Hyodo T, Kumano K, Haga M, Sakai T, Fukuda M, Isami Y, et al. The validity of the criteria to differentiate the origin of hematuria in the automated urinary flow cytometer. *Nephron* 1997;75:112.
- Hyodo T, Kumano K, Sakai T. Differential diagnosis between glomerular and nonglomerular hematuria by automated urinary flow cytometer. *Nephron* 1999;82:312-23.
- Kore RN, Dow CS, Desai KM. A new automated system for urine analysis: a simple, cost-effective and reliable method for distinguishing between glomerular and nonglomerular sources of haematuria. *BJU International* 1999;84:454-60.
- Game X, Soulie M, Fontanilles AM, Benoit JM, Corberand JX, Plante P. Comparison of red blood cell volume distribution curves and phase-contrast microscopy in localization of the origin of hematuria. *Urology* 2003;61:507-11.
- Kaneko K, Murakami M, Shiraishi K, Matsumoto M, Yamauchi K, Kitagawa T, et al. Usefulness of an automated urinary flow cytometer in mass screening for nephritis. *Pediatr Nephrol* 2004;19:499-502.
- Kincaid-Smith P, Fairley K. The investigation of hematuria. *Semin Nephrol* 2005;25:127-35.
- Scharnhorst V, Gerlag PG, Nanlohy Manuhutu ML, van der Graaf F. Urine flow cytometry and detection of glomerular hematuria. *Clin Chem Lab Med* 2006;44:1330-4.
- Tanaka M, Kitamoto Y, Sato T, Ishii T. Flow cytometric analysis of hematuria using fluorescent antihemoglobin antibody. *Nephron* 1993;65:354-8.